

BMJ

ABC of clinical electrocardiography: Junctional tachycardias

Demas Esberger, Sallyann Jones and Francis Morris

BMJ 2002;324:662-665
doi:10.1136/bmj.324.7338.662

Updated information and services can be found at:
<http://bmj.com/cgi/content/full/324/7338/662>

These include:

Rapid responses

One rapid response has been posted to this article, which you can access for free at:

<http://bmj.com/cgi/content/full/324/7338/662#responses>

You can respond to this article at:

<http://bmj.com/cgi/eletter-submit/324/7338/662>

Email alerting service

Receive free email alerts when new articles cite this article - sign up in the box at the top left of the article

Topic collections

Articles on similar topics can be found in the following collections

[Arrhythmias](#) (727 articles)

Notes

To order reprints follow the "Request Permissions" link in the navigation box

To subscribe to *BMJ* go to:

<http://resources.bmj.com/bmj/subscribers>

ABC of clinical electrocardiography

Junctional tachycardias

Demas Esberger, Sallyann Jones, Francis Morris

Any tachyarrhythmia arising from the atria or the atrioventricular junction is a supraventricular tachycardia. In clinical practice, however, the term supraventricular tachycardia is reserved for atrial tachycardias and arrhythmias arising from the region of the atrioventricular junction as a result of a re-entry mechanism (junctional tachycardias). The most common junctional tachycardias are atrioventricular nodal re-entrant tachycardia and atrioventricular re-entrant tachycardia.

Atrioventricular nodal re-entrant tachycardia

This is the most common cause of paroxysmal regular narrow complex tachycardia. Affected individuals are usually young and healthy with no organic heart disease.

Mechanism

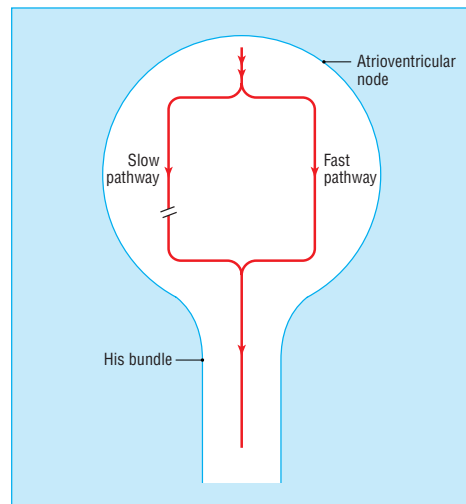
In atrioventricular nodal re-entrant tachycardia there are two functionally and anatomically different distinct pathways in the atrioventricular node, with different conduction velocities and different refractory periods. They share a final common pathway through the lower part of the atrioventricular node and bundle of His. One pathway is relatively fast and has a long refractory period; the other pathway is slow with a short refractory period. In sinus rhythm the atrial impulse is conducted through the fast pathway and depolarises the ventricles. The impulse also travels down the slow pathway but terminates because the final common pathway is refractory.

The slow pathway has a short refractory period and recovers first. An atrioventricular nodal re-entrant tachycardia is initiated, for example, if a premature atrial beat occurs at the critical moment when the fast pathway is still refractory. The impulse is conducted through the slow pathway and is then propagated in a retrograde fashion up the fast pathway, which has by now recovered from its refractory period. Thus a re-entry through the circuit is created.

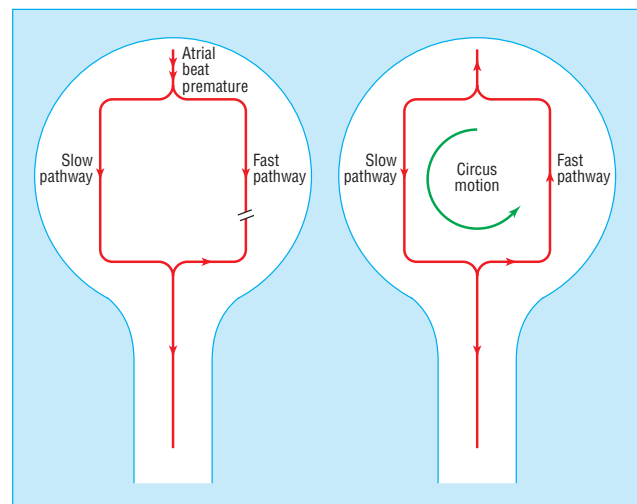
This type of "slow-fast" re-entry circuit is found in 90% of patients with atrioventricular nodal re-entrant tachycardia. Most of the rest have a fast-slow circuit, in which the re-entrant tachycardia is initiated by a premature ventricular contraction, and the impulse travels retrogradely up the slow pathway. This uncommon form of atrioventricular nodal re-entrant tachycardia is often sustained for very long periods and is then known as permanent junctional re-entrant tachycardia and is recognised by a long RP¹ interval.

Electrocardiographic findings

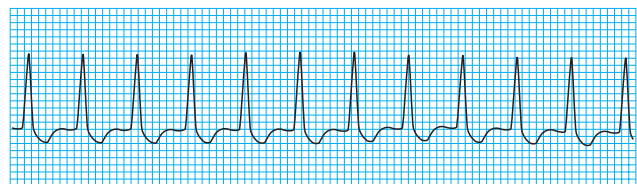During sinus rhythm the electrocardiogram is normal. During the tachycardia the rhythm is regular, with narrow QRS complexes and a rate of 130-250 beats/min. Atrial conduction proceeds in a retrograde fashion producing inverted P waves in leads II, III, and aVF. However, since atrial and ventricular depolarisation often occurs simultaneously, the P waves are frequently buried in the QRS complex and may be totally obscured. A P wave may be seen distorting the last part of the QRS complex giving rise to a "pseudo" S wave in the inferior leads and a "pseudo" R wave in V1.



Mechanism of atrioventricular nodal re-entrant tachycardia showing the slow and fast conduction routes and the final common pathway through the lower part of the atrioventricular node and bundle of His



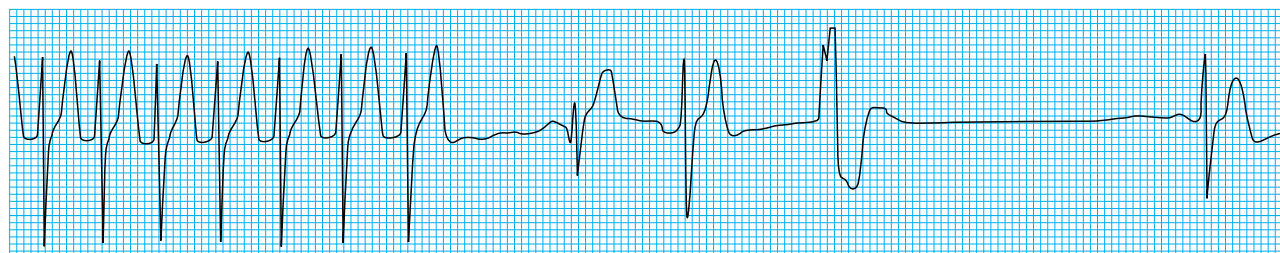
A premature atrial impulse finds the fast pathway refractory, allowing conduction only down the slow pathway (left). By the time the impulse reaches the His bundle, the fast pathway may have recovered, allowing retrograde conduction back up to the atria—the resultant "circus movement" gives rise to slow-fast atrioventricular nodal re-entrant tachycardia (right)



An atrioventricular nodal re-entrant tachycardia

In the relatively uncommon fast-slow atrioventricular nodal re-entrant tachycardia, atrial depolarisation lags behind depolarisation of the ventricles, and inverted P waves may follow the T wave and precede the next QRS complex.

Fast-slow atrioventricular nodal re-entrant tachycardia is known as long RP' tachycardia, and it may be difficult to distinguish from an atrial tachycardia



Termination of atrioventricular nodal re-entrant tachycardia

Clinical presentation

Episodes of atrioventricular nodal re-entrant tachycardia may begin at any age. They tend to start and stop abruptly and can occur spontaneously or be precipitated by simple movements. They can last a few seconds, several hours, or days. The frequency of episodes can vary between several a day, or one episode in a lifetime. Most patients have only mild symptoms, such as palpitations or the sensation that their heart is beating rapidly. More severe symptoms include dizziness, dyspnoea, weakness, neck pulsation, and central chest pain. Some patients report polyuria.

Symptoms are commonest in patients with a very rapid heart rate and pre-existing heart disease

Atrioventricular re-entrant tachycardia

Atrioventricular re-entrant tachycardias occur as a result of an anatomically distinct atrioventricular connection. This accessory conduction pathway allows the atrial impulse to bypass the atrioventricular node and activate the ventricles prematurely (ventricular pre-excitation). The presence of the accessory pathway allows a re-entry circuit to form and paroxysmal atrioventricular re-entrant tachycardias to occur.

Wolff-Parkinson-White syndrome

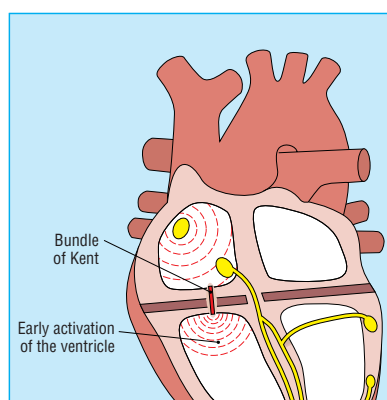
In this syndrome an accessory pathway (the bundle of Kent) connects the atria directly to the ventricles. It results from a failure of complete separation of the atria and ventricles during fetal development.

The pathway can be situated anywhere around the groove between the atria and ventricles, and in 10% of cases more than one accessory pathway exists. The accessory pathway allows the formation of a re-entry circuit, which may give rise to either a narrow or a broad complex tachycardia, depending on whether the atrioventricular node or the accessory pathway is used for antegrade conduction.

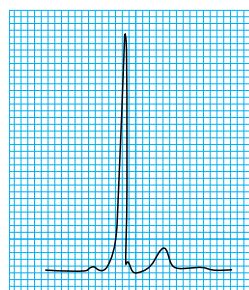
Electrocardiographic features

In sinus rhythm the atrial impulse conducts over the accessory pathway without the delay encountered with atrioventricular nodal conduction. It is transmitted rapidly to the ventricular myocardium, and consequently the PR interval is short. However, because the impulse enters non-specialised myocardium, ventricular depolarisation progresses slowly at first, distorting the early part of the R wave and producing the characteristic delta wave on the electrocardiogram. This slow depolarisation is then rapidly overtaken by depolarisation propagated by the normal conduction system, and the rest of the QRS complex appears relatively normal.

The commonest kind of atrioventricular re-entrant tachycardia occurs as part of the Wolff-Parkinson-White syndrome



In the Wolff-Parkinson-White syndrome the bundle of Kent provides a separate electrical conduit between the atria and the ventricles



In sinus rhythm conduction over the accessory pathway gives rise to a short PR interval and a delta wave

Commonly, the accessory pathway is concealed—that is, it is capable of conducting only in a retrograde fashion, from ventricles to atria. During sinus rhythm pre-excitation does not occur and the electrocardiogram is normal.

Traditionally the Wolff-Parkinson-White syndrome has been classified into two types according to the electrocardiographic morphology of the precordial leads. In type A, the delta wave and QRS complex are predominantly upright in the precordial leads. The dominant R wave in lead V1 may be misinterpreted as right bundle branch block. In type B, the delta wave and QRS complex are predominantly negative in leads V1 and V2 and positive in the other precordial leads, resembling left bundle branch block.

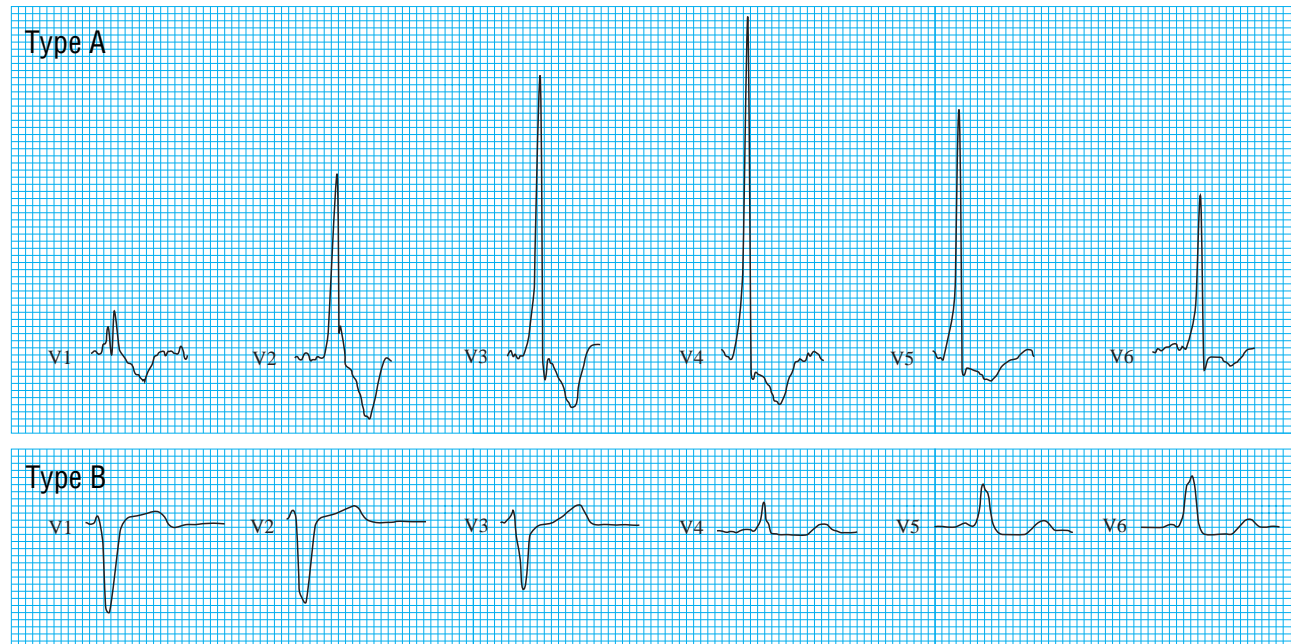Classification of Wolff-Parkinson-White syndrome

Type A (dominant R wave in V1 lead) may be confused with:

- Right bundle branch block
- Right ventricular hypertrophy
- Posterior myocardial infarction

Type B (negative QRS complex in V1 lead) may be confused with:

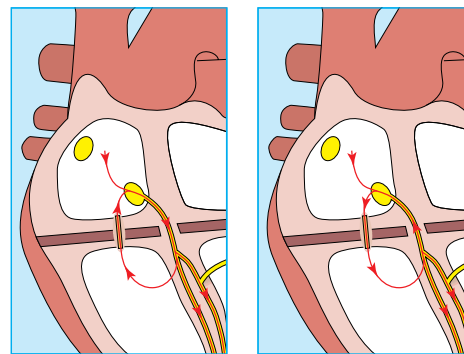
- Left bundle branch block
- Anterior myocardial infarction



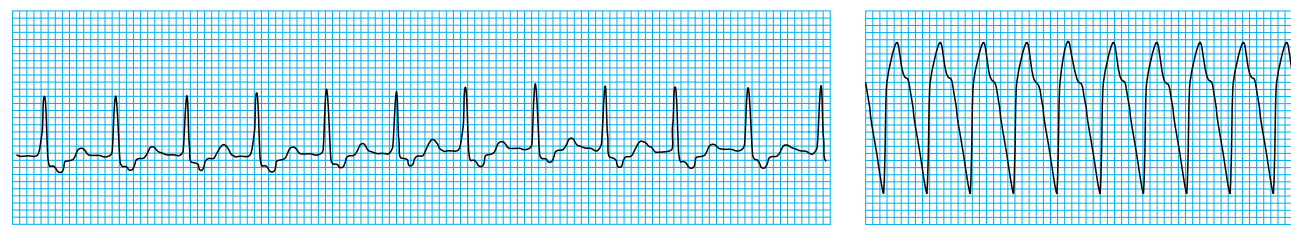Wolff-Parkinson-White, type A and type B, characterised by morphology of the recording from leads V1 to V6

Mechanism of tachycardia formation

Orthodromic atrioventricular re-entrant tachycardias account for most tachycardias in the Wolff-Parkinson-White syndrome. A premature atrial impulse is conducted down the atrioventricular node to the ventricles and then in a retrograde fashion via the accessory pathway back to the atria. The impulse then circles repeatedly between the atria and ventricles, producing a narrow complex tachycardia. Since atrial depolarisation lags behind ventricular depolarisation, P waves follow the QRS complexes. The delta wave is not observed during the tachycardia, and the QRS complex is of normal duration. The rate is usually 140-250 beats/min.



Mechanisms for orthodromic (left) and antidromic (right) atrioventricular re-entrant tachycardia

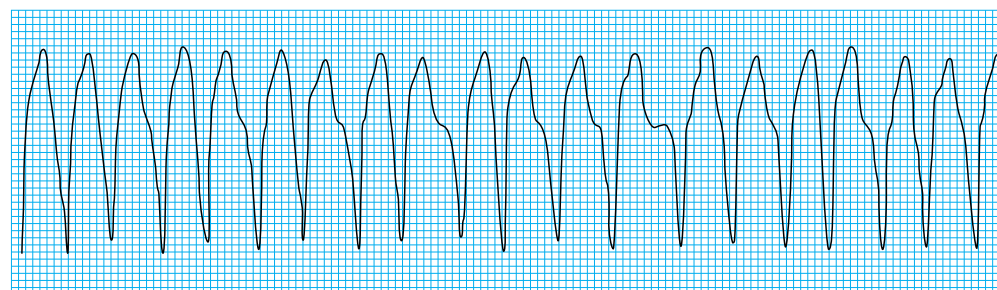


Orthodromic atrioventricular re-entrant tachycardia (left) showing clearly visible inverted P waves following the QRS complex, and antidromic atrioventricular re-entrant tachycardia (right) in the Wolff-Parkinson-White syndrome showing broad complexes

Antidromic atrioventricular re-entrant tachycardia is relatively uncommon, occurring in about 10% of patients with the Wolff-Parkinson-White syndrome. The accessory pathway allows antegrade conduction, and thus the impulse is conducted from the atria to the ventricles via the accessory pathway. Depolarisation is propagated through non-specialised myocardium, and the resulting QRS complex is broad and bizarre. The impulse then travels in a retrograde fashion via the atrioventricular node back to the atria.

Atrial fibrillation

In patients without an accessory pathway the atrioventricular node protects the ventricles from the rapid atrial activity that occurs during atrial fibrillation. In the Wolff-Parkinson-White syndrome the atrial impulses can be conducted via the accessory pathway, causing ventricular pre-excitation and producing broad QRS complexes with delta waves. Occasionally an impulse will be conducted via the atrioventricular node and produce a normal QRS complex. The electrocardiogram has a characteristic appearance, showing a rapid, completely irregular broad complex tachycardia but with occasional narrow complexes.



Atrial fibrillation in the Wolff-Parkinson-White syndrome

Clinical presentation

The Wolff-Parkinson-White syndrome is sometimes an incidental electrocardiographic finding, but often patients present with tachyarrhythmias. Episodes tend to be more common in young people but may come and go through life. Patients may first present when they are old.

When rapid arrhythmias occur in association with atrial fibrillation, patients may present with heart failure or hypotension. Drugs that block the atrioventricular node—for example, digoxin, verapamil, and adenosine—may be dangerous in this situation and should be avoided. These drugs decrease the refractoriness of accessory connections and increase the frequency of conduction, resulting in a rapid ventricular response, which may precipitate ventricular fibrillation.

Orthodromic atrioventricular re-entrant tachycardia occurs with antegrade conduction through the atrioventricular node

Antidromic atrioventricular re-entrant tachycardia occurs with retrograde conduction through the atrioventricular node

In some patients the accessory pathway allows very rapid conduction, and consequently very fast ventricular rates (in excess of 300 beats/min) may be seen, with the associated risk of deterioration into ventricular fibrillation

Demas Esberger is consultant in accident and emergency medicine and Sallyann Jones is specialist registrar in accident and emergency medicine at the Queen's Medical Centre, Nottingham.

The ABC of clinical electrocardiography is edited by Francis Morris, consultant in emergency medicine at the Northern General Hospital, Sheffield; June Edhouse, consultant in emergency medicine, Stepping Hill Hospital, Stockport; William J Brady, associate professor, programme director, and vice chair, department of emergency medicine, University of Virginia, Charlottesville, VA, USA; and John Camm, professor of clinical cardiology, St George's Hospital Medical School, London. The series will be published as a book in the summer.

BMJ 2002;324:662-5

One hundred years ago

Strike of American army nurses

According to the *New York Medical Journal* a number of the female army nurses concerned in the recent strike at the General Hospital in Manila reached San Francisco recently on the transports *Rosencrans* and *Hancock*, and are now at the General Hospital awaiting further orders. The cause of the strike was an order obliging them to wash dishes in addition to their other duties. At the time they left Manila the situation was very tense, about 100 of the women on duty as nurses in the hospital having refused to go on with their regular duties unless the obnoxious order was rescinded. By this time some change of a radical nature must have taken place, as Colonel B. F. Pope, who was Chief Surgeon at Manila at the time of the strike, has died since the

Hancock and *Rosencrans* left Manila. The nurses said they were perfectly willing to wash dishes if it were necessary, but that they had spent both money and time on a special form of training, and they thought their duties should be confined to nursing, while the dish washing should be done by hired Filipino servants. The strike began by their holding a mass meeting and resolving to leave in a body for the United States proper unless the order was revoked. Mrs. Kinney, the chief nurse in the army, who is on a tour of inspection in the Philippines, supported the nurses in their strike, and public sentiment in Manila is also said to be strong in their favour.

(*BMJ* 1902;i:851)