

ABC of clinical electrocardiography

Broad complex tachycardia—Part II

June Edhouse, Francis Morris

This article continues the discussion, started last week, on ventricular tachycardias and also examines how to determine whether a broad complex tachycardia is ventricular or supraventricular in origin.

Ventricular tachycardias

Fascicular tachycardia

Fascicular tachycardia is uncommon and not usually associated with underlying structural heart disease. It originates from the region of the posterior fascicle (or occasionally the anterior fascicle) of the left bundle branch and is partly propagated by the His-Purkinje network. It therefore produces QRS complexes of relatively short duration (0.11-0.14 s). Consequently, this arrhythmia is commonly misdiagnosed as a supraventricular tachycardia.

The QRS complexes have a right bundle branch block pattern, often with a small Q wave rather than primary R wave in lead V1 and a deep S wave in lead V6. When the tachycardia originates from the posterior fascicle the frontal plane axis of the QRS complex is deviated to the left; when it originates from the anterior fascicle, right axis deviation is seen.

Right ventricular outflow tract tachycardia

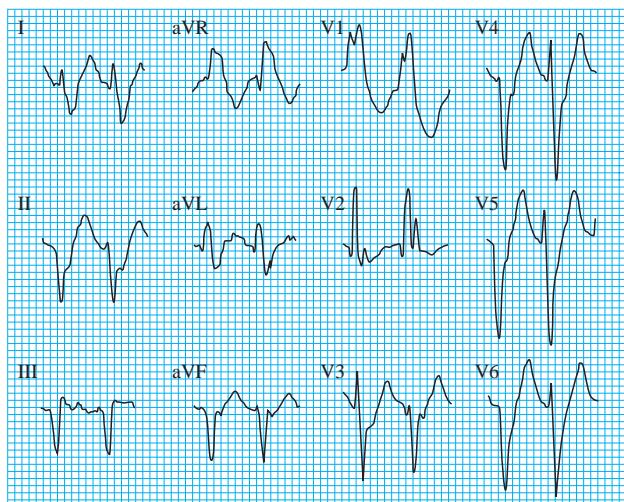
This tachycardia originates from the right ventricular outflow tract, and the impulse spreads inferiorly. The electrocardiogram typically shows right axis deviation, with a left bundle branch block pattern. The tachycardia may be brief and self terminating or sustained, and it may be provoked by catecholamine release, sudden changes in heart rate, and exercise. The tachycardia usually responds to drugs such as β blockers or calcium antagonists. Occasionally the arrhythmia stops with adenosine treatment and so may be misdiagnosed as a supraventricular tachycardia.

Torsades de pointes tachycardia

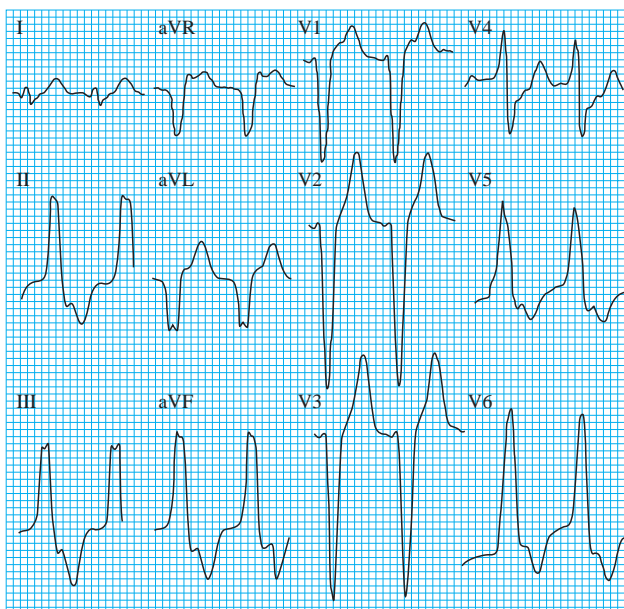Torsades de pointes ("twisting of points") is a type of polymorphic ventricular tachycardia in which the cardiac axis rotates over a sequence of 5-20 beats, changing from one direction to another and back again. The QRS amplitude varies similarly, such that the complexes appear to twist around the baseline. In sinus rhythm the QT interval is prolonged and prominent U waves may be seen.

Torsades de pointes is not usually sustained, but it will recur unless the underlying cause is corrected. Occasionally it may be prolonged or degenerate into ventricular fibrillation. It is associated with conditions that prolong the QT interval.

Transient prolongation of the QT interval is often seen in the acute phase of myocardial infarction, and this may lead to

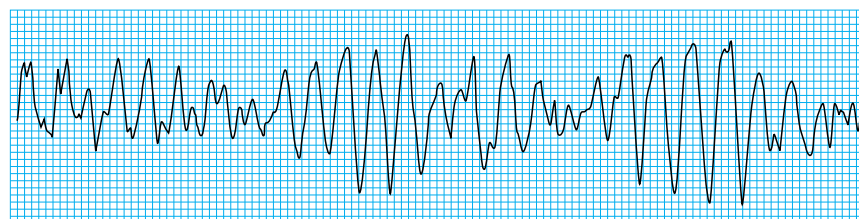


Fascicular ventricular tachycardia (note the right bundle branch block pattern and left axis deviation)



Right ventricular outflow tract tachycardia

Torsades de pointes may be drug induced or secondary to electrolyte disturbances

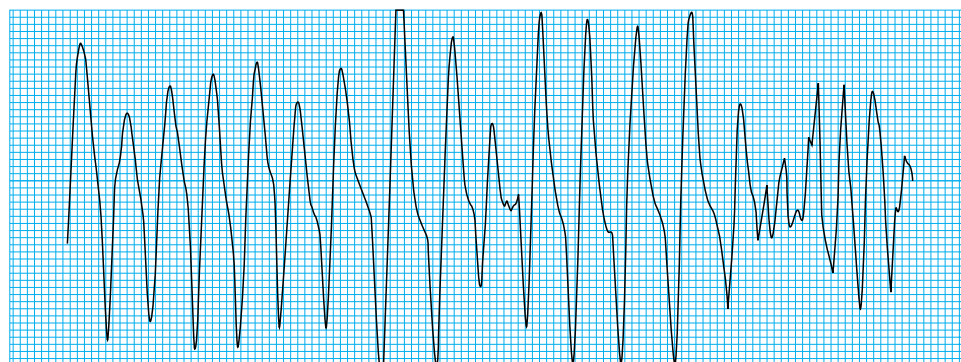


Torsades de pointes

torsades de pointes. Ability to recognise torsades de pointes is important because its management is different from the management of other ventricular tachycardias.

Polymorphic ventricular tachycardia

Polymorphic ventricular tachycardia has the electrocardiographic characteristics of torsades de pointes but in sinus rhythm the QT interval is normal. It is much less common than torsades de pointes. If sustained, polymorphic ventricular tachycardia often leads to haemodynamic collapse. It can occur in acute myocardial infarction and may deteriorate into ventricular fibrillation. Polymorphic ventricular tachycardia must be differentiated from atrial fibrillation with pre-excitation, as both have the appearance of an irregular broad complex tachycardia with variable QRS morphology (see last week's article).



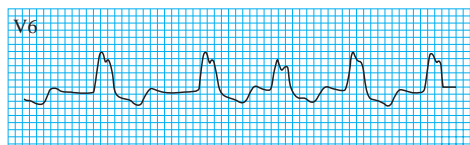
Polymorphic ventricular tachycardia deteriorating into ventricular fibrillation

Broad complex tachycardias of supraventricular origin

In the presence of aberrant conduction or ventricular pre-excitation, any supraventricular tachycardia may present as a broad complex tachycardia and mimic ventricular tachycardia.

Atrial tachycardia with aberrant conduction

Aberrant conduction is defined as conduction through the atrioventricular node with delay or block, resulting in a broader QRS complex. Aberrant conduction usually manifests as left or right bundle branch block, both of which have characteristic features. The bundle branch block may predate the tachycardia, or it may be a rate related functional block, occurring when atrial impulses arrive too rapidly for a bundle branch to conduct normally. When atrial fibrillation occurs with aberrant conduction and a rapid ventricular response, a totally irregular broad complex tachycardia is produced.



Atrial fibrillation and left bundle branch block

Wolff-Parkinson-White syndrome

Broad complex tachycardias may also occur in the Wolff-Parkinson-White syndrome, either as an antidromic atrioventricular re-entrant tachycardia or in association with atrial flutter or fibrillation.

Causes of torsades de pointes

Drugs

- Antiarrhythmic drugs: class Ia (disopyramide, procainamide, quinidine); class III (amiodarone, bretylium, sotalol)
- Antibacterials: erythromycin, fluoroquinolones, trimethoprim
- Other drugs: terfenadine, cisapride, tricyclic antidepressants, haloperidol, lithium, phenothiazines, chloroquine, thioridazine

Electrolyte disturbances

- Hypokalaemia
- Hypomagnesaemia

Congenital syndromes

- Jervell and Lange-Nielsen syndrome
- Romano-Ward syndrome

Other causes

- Ischaemic heart disease
- Myxoedema
- Bradycardia due to sick sinus syndrome or complete heart block
- Subarachnoid haemorrhage

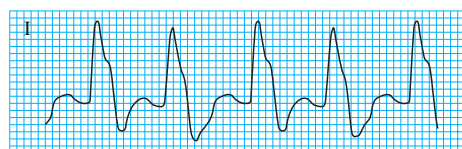
Differentiation between ventricular tachycardia and supraventricular tachycardia with bundle branch block

If the tachycardia has a right bundle branch block morphology (a predominantly positive QRS complex in lead V1), a ventricular origin is suggested if there is:

- QRS complex with duration >0.14 s
- Axis deviation
- A QS wave or predominantly negative complex in lead V6
- Concordance throughout the chest leads, with all deflections positive
- A single (R) or biphasic (QR or RS) R wave in lead V1
- A triphasic R wave in lead V1, with the initial R wave taller than the secondary R wave and an S wave that passes through the isoelectric line

If the tachycardia has a left bundle branch block morphology (a predominantly negative deflection in lead V1), a ventricular origin is suggested if there is:

- Axis deviation
- QRS complexes with duration >0.16 s
- A QS or predominantly negative deflection in lead V6
- Concordance throughout the chest leads, with all deflections negative
- An rS complex in lead V1



Atrial flutter with left bundle branch block, giving rise to broad complex tachycardia

The Wolff-Parkinson-White syndrome is discussed in more detail in an earlier article, on junctional tachycardias

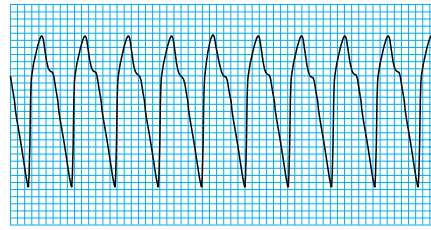
Antidromic atrioventricular re-entrant tachycardia

In this relatively uncommon tachycardia the impulse is conducted from the atria to the ventricles via the accessory pathway. The resulting tachycardia has broad, bizarre QRS complexes.

Atrial fibrillation

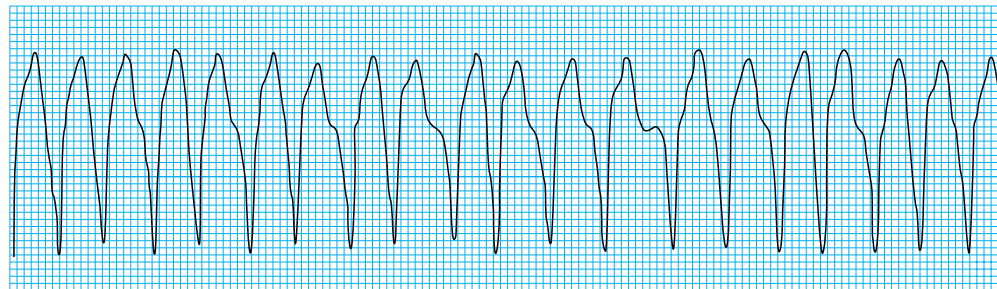
In patients without an accessory pathway the atrioventricular node protects the ventricles from the rapid atrial activity that occurs during atrial fibrillation. In the Wolff-Parkinson-White syndrome the atrial impulses are conducted down the accessory pathway, which may allow rapid conduction and consequently very fast ventricular rates.

The impulses conducted via the accessory pathway produce broad QRS complexes. Occasionally an impulse will be conducted via the atrioventricular node and produce a normal QRS complex or a fusion beat. The result is a completely irregular and often rapid broad complex tachycardia with a fairly constant QRS pattern, except for occasional normal complexes and fusion beats.



Antidromic atrioventricular re-entrant tachycardia, giving rise to broad complex tachycardia

Drugs that block the atrioventricular node—such as digoxin, verapamil, and adenosine—should be avoided as they can produce an extremely rapid ventricular response



Atrial fibrillation in patient with Wolff-Parkinson-White syndrome (note irregularity of complexes)

Differentiating between ventricular and supraventricular origin

Clinical presentation

Age is a useful factor in determining the origin of a broad complex tachycardia: a tachycardia in patients aged over 35 years is more likely to be ventricular in origin. A history that includes ischaemic heart disease or congestive cardiac failure is 90% predictive of ventricular tachycardia.

The symptoms associated with broad complex tachycardia depend on the haemodynamic consequences of the arrhythmia—that is, they relate to the heart rate and the underlying cardiac reserve rather than to the origin of the arrhythmia. It is wrong to assume that a patient with ventricular tachycardia will inevitably be in a state of collapse; some patients look well but present with dizziness, palpitations, syncope, chest pain, or heart failure. In contrast, a supraventricular tachycardia may cause collapse in a patient with underlying poor ventricular function.

Clinical evidence of atrioventricular dissociation—that is, “cannon” waves in the jugular venous pulse or variable intensity of the first heart sound—indicates a diagnosis of a ventricular tachycardia. The absence of these findings, however, does not exclude the diagnosis.

Electrocardiographic differences

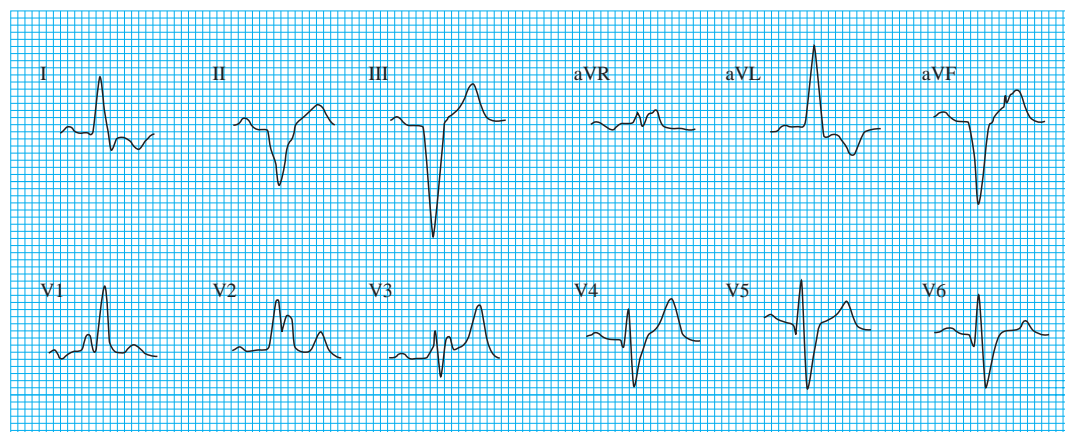
Direct evidence of independent P wave activity is highly suggestive of ventricular tachycardia, as is the presence of fusion beats or captured beats. The duration of QRS complexes is also a key differentiating feature: those of >0.14 s generally indicate a ventricular origin. Concordance throughout the chest leads also indicates ventricular tachycardia.

Danger of misdiagnosis

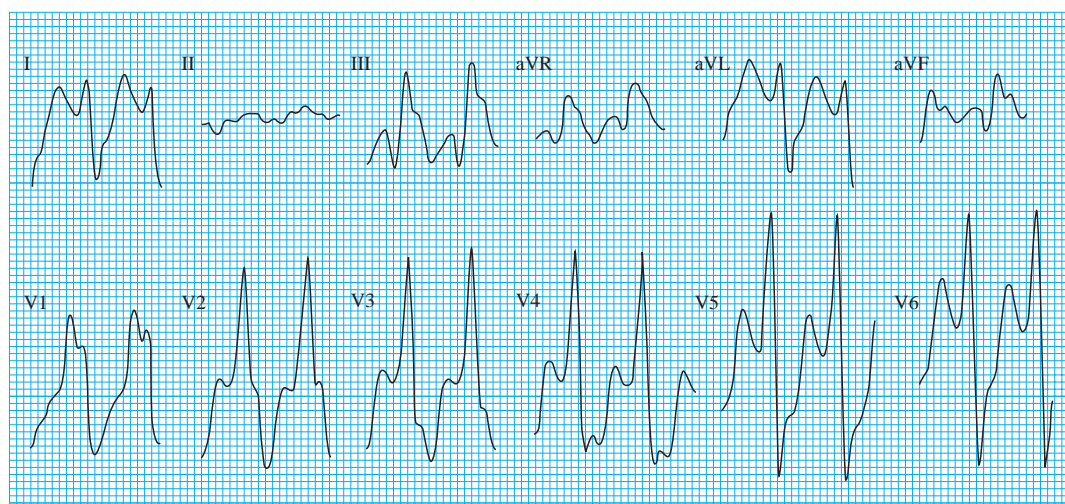
- The safest option is to regard a broad complex tachycardia of uncertain origin as ventricular tachycardia unless good evidence suggests a supraventricular origin
- If a ventricular tachycardia is wrongly treated as supraventricular tachycardia, the consequences may be extremely serious
- Giving verapamil to a patient with ventricular tachycardia may result in hypotension, acceleration of the tachycardia, and death

In ventricular tachycardia the rhythm is regular or almost regular; if the rhythm is obviously irregular the most likely diagnosis is atrial fibrillation with either aberrant conduction or pre-excitation

A previous electrocardiogram may give valuable information. Evidence of a myocardial infarction increases the likelihood of ventricular tachycardia, and if the mean frontal plane axis changes during the tachycardia (especially if the change is $>40^\circ$ to the left or right) this points to a ventricular origin.



Left axis deviation and right bundle branch block in man with previous inferior myocardial infarction



Monomorphic ventricular tachycardia in same patient, showing a shift of axis to right of $>40^\circ$ (note positive concordance)

Ventricular tachycardia and supraventricular tachycardia with bundle branch block may produce similar electrocardiograms. If a previous electrocardiogram shows a bundle branch block pattern during sinus rhythm that is similar to or identical with that during the tachycardia, the origin of the tachycardia is likely to be supraventricular. But if the QRS morphology changes during the tachycardia, a ventricular origin is indicated.

The emergency management of a broad complex tachycardia depends on the wellbeing of the patient and the origin of the arrhythmia. Vagal stimulation—for example, carotid sinus massage or the Valsalva manoeuvre—does not usually affect a ventricular tachycardia but may affect arrhythmias of supraventricular origin. By transiently slowing or blocking conduction through the atrioventricular node, an atrioventricular nodal re-entrant tachycardia or atrioventricular re-entrant tachycardia may be terminated. In atrial flutter transient block may reveal the underlying flutter waves.

Adenosine can also be used to block conduction temporarily through the atrioventricular node to ascertain the origin of a broad complex tachycardia, but failure to stop the tachycardia does not necessarily indicate a ventricular origin

The ABC of clinical electrocardiography is edited by Francis Morris, consultant in emergency medicine at the Northern General Hospital, Sheffield; June Edhouse, consultant in emergency medicine, Stepping Hill Hospital, Stockport; William J Brady, associate professor, programme director, and vice chair, department of emergency medicine, University of Virginia, Charlottesville, VA, USA; and John Camm, professor of clinical cardiology, St George's Hospital Medical School, London. The series will be published as a book in the summer.

BMJ 2002;324:776-9